Chirurgie des immobilités cordales en fermeture selon la technique de G. LICHTENBERGER

SFPPC 2006

B. Coulombeau, R. Pérouse, Lyon

C. Arias, C. Casanova, Barcelona

Introduction

- Situation du problème
  - Aigu
  - Chronique
- Historique
  - Cordectomie postérieure laser (« transverse »)
  - Aryténoïdectomie laser
  - Aryténoïdopexie
    - King
    - Kelly

SFPPC 2006

Aspects techniques

Instrument Set

1

2

3

1. Loading suture
2. Loading position
3. Suture locked and ready

This needle-carrier instrument was developed to simplify laterofixation in operations to expand the glottis.
The instrument's design makes it extremely safe and easy to use.

Needle-carrier instrument by Lichtenberger including 20 needles 8267.50

Aspects techniques

- La focale 400 mm
- Le fil monobrin
- Le contre-appui
- L’enfouissement

SFPPC 2006

Aspects techniques

Operation methods

by G. Lichtenberger based on the endo-extralaryngeal suture technique

REExL (Reversible Endo-Extralaryngeal Lateralization)

This procedure is indicated directly after the development of the paralysis, if the vocal cords are in paramedian position, but it is not sure that their paralysis is irreversible (e.g. directly after thyroid surgery). The application of this method allows the avoidance of tracheostomy. JET anaesthesia is advised.

This procedure using the device can be carried out for temporary lateralization of the vocal cords. The ends of the threads are tied under the skin above the sternohyoid muscle on one side.

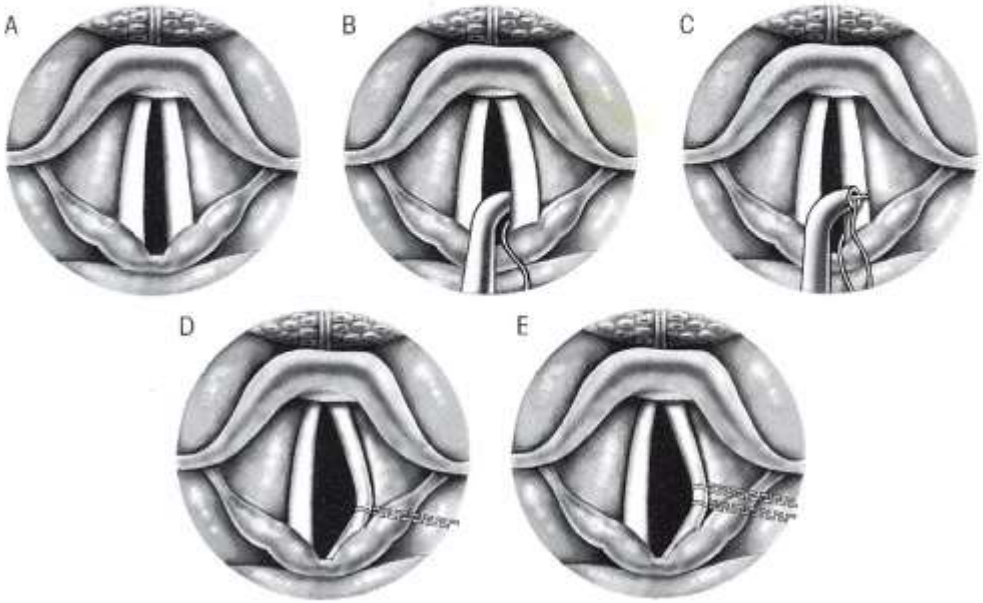

Cas particulier des synéchies postérieures

Temporary lateralization of the vocal cords after dividing the scars in the posterior commissura.

This technique is indicated if the vocal cords are fixed in paramedian position by scars not bigger than 5 millimetres in the posterior commissura, and if the vocal cords are not paralysed (proved by EMG).

To prevent readhesion, the vocal cords will – after dividing the scars in the posterior commissura – be lateralized temporarily. Using the above technique in JET anaesthesia, tracheostomy will not be necessary. The ends of the thread will be knotted above the bent silicone tube placed on the skin of the neck on both sides. The threads will be removed four weeks after surgery.

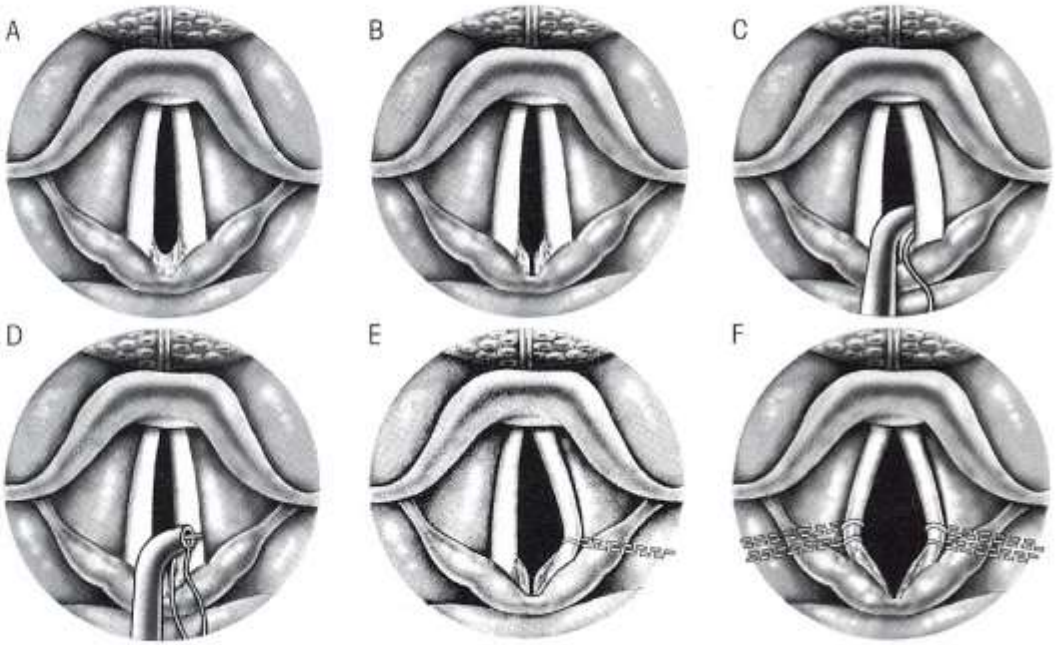

Avantages

- Simplicité
- Efficacité
- Réversibilité <1 mois
- Sevrage/dispense trachéotomie

SFPPC 2006

Inconvénients

- Antériorisation du fil si sonde
- Réactions inflammatoires (int. ou ext.)
- Encoche permanente après un mois
- Dispositif onéreux

SFPPC 2006

Cas clinique

- Mme MS, 62 ans
- Thyroïdectomie totale le 9/11/2005 pour goître MN sur thyroïdite d ’Hashimoto
- Dyspnée dès l ’extubation, nécessitant une ré-intubation et trachéotomie au bout de 24 heures.
- VP
- VCh

SFPPC 2006

Cas clinique

- Mme MS, 62 ans
- Intervention le 15 février 2006

SFPPC 2006

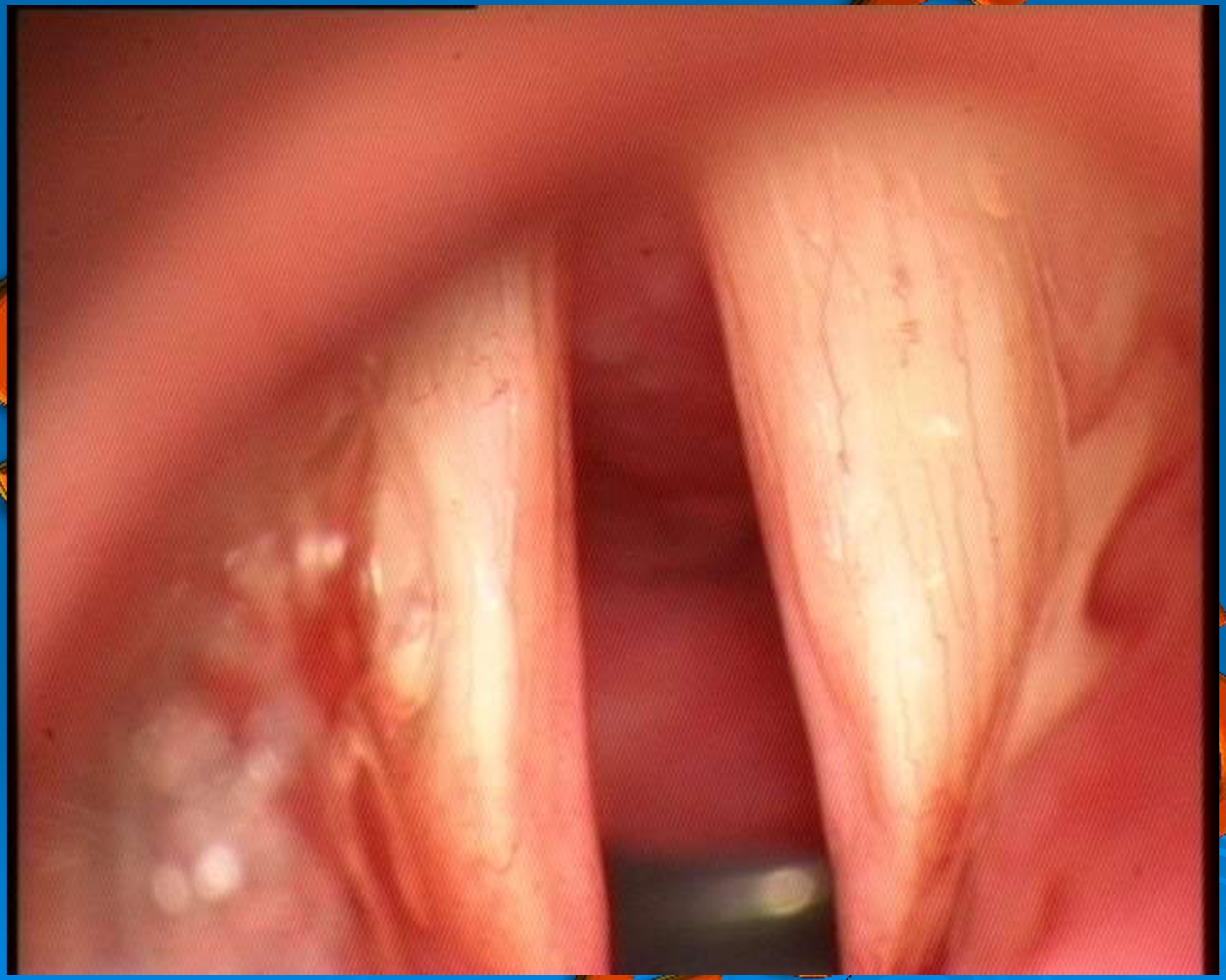

Cas clinique

- Mme MS, 62 ans
- Trachéotomie refermée durant l ’intervention
- Rééducation vocale assurée ici par le Dr Cori Casanova
- Résultat à 7 mois (26 septembre 2006)
- VP
- VCh

SFPPC 2006

J2 - Premier postop

Discussion

- Intervention princeps actuellement
- Moins délabrante que le laser
- Permet l'acquisition d'un compromis
- Peut être couplée à la Mitomycine
- Sous-abduction toujours corrigeable

SFPPC 2006

Conclusion

- Intervention à faire connaître
- Prend sa place en phase aiguë
- N’entraîne rien d’irrémédiable

SFPPC

2006